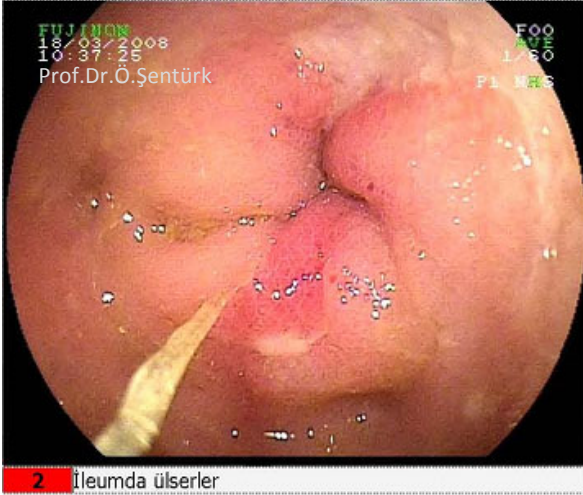
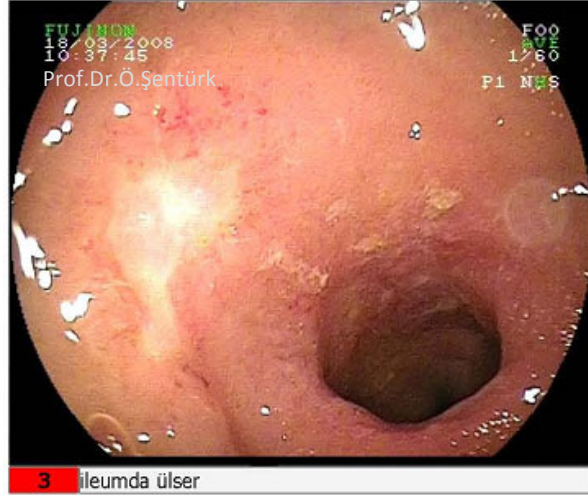

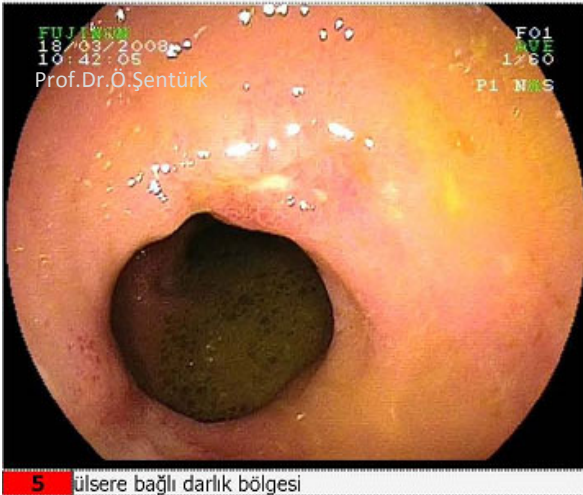Çift Balonlu Enteroskopi (Double Balloon Enteroscopy)



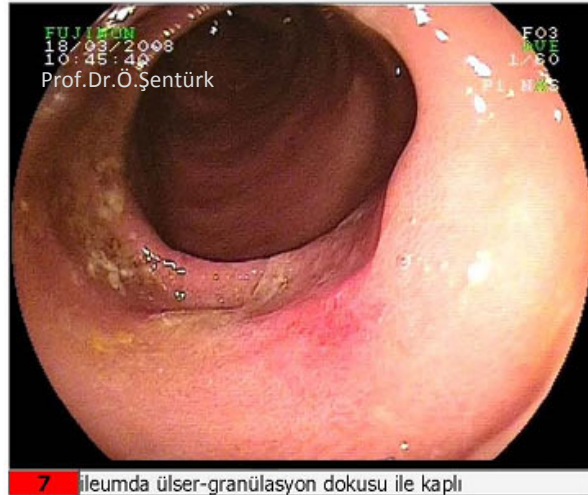2 İleumda ülserler



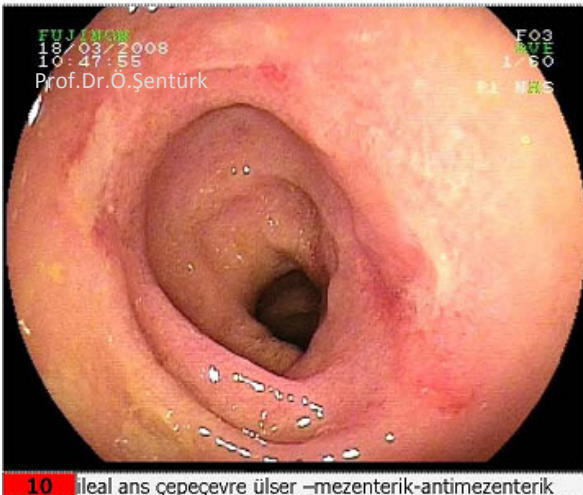
3 İleumda ülser



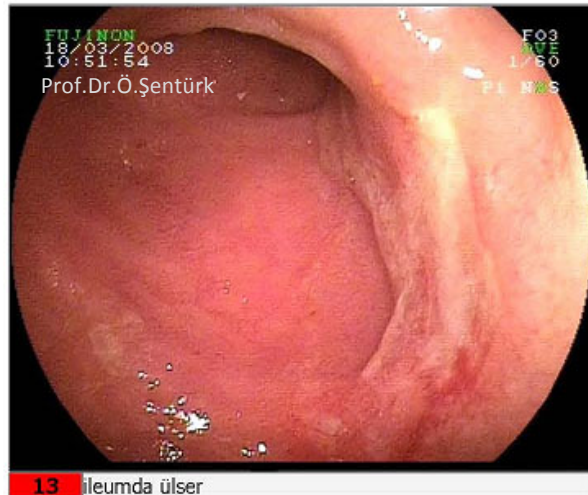
5 Ülsere bağlı darlık bölgesi



7 İleumda ülser-granülasyon dokusu ile kaplı

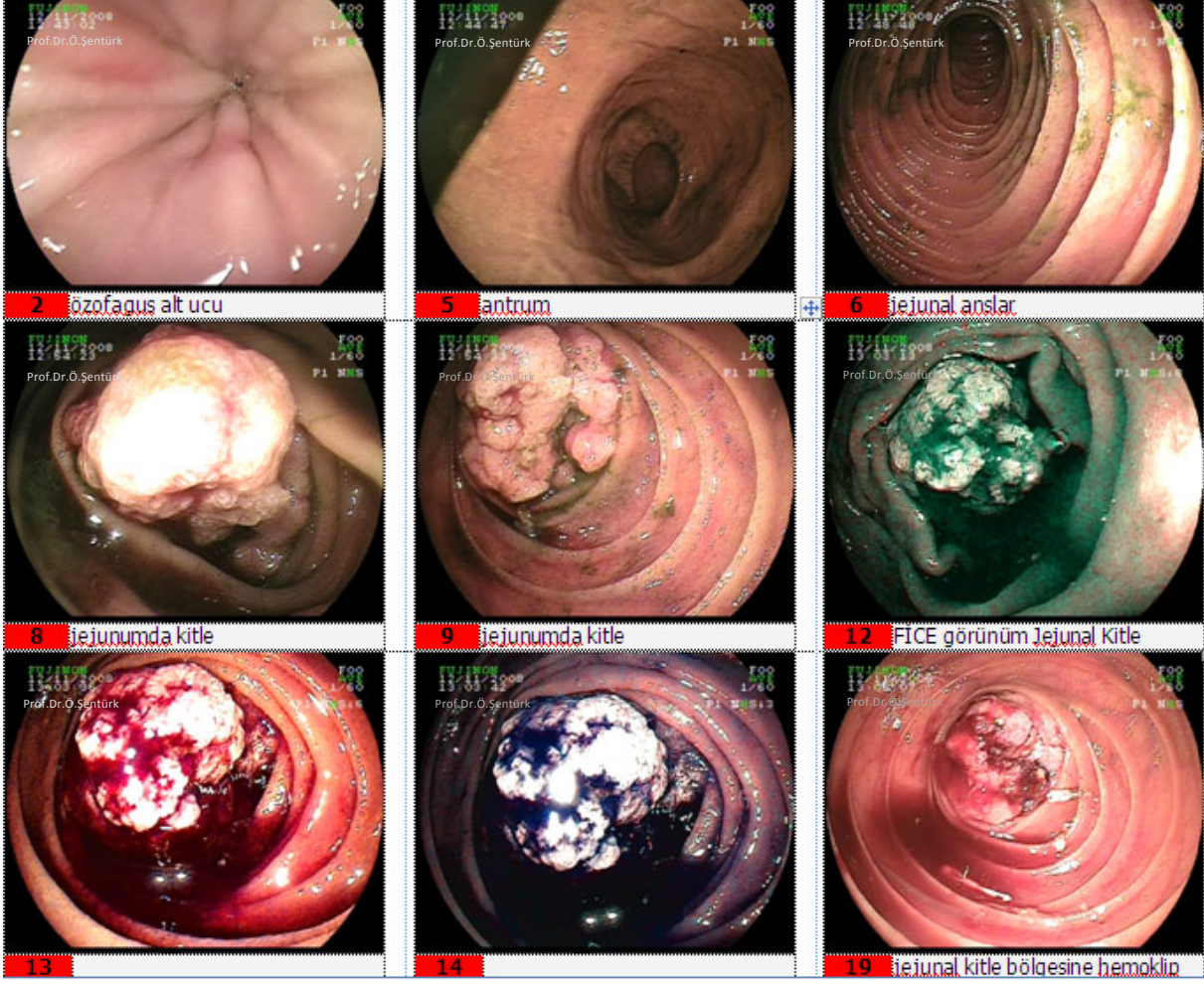


10 İleal ans çepeçevre ülser -mezenterik-antimezenterik



13 İleumda ülser

Çift balonlu enteroskopi ile saptanan ince barsak tümörü



Çift balonlu enteroskopi ile saptanan Çölyak Hastalığı zemininde Lenfoma

